

# SCD Case Study

## Implant-supported overdentures

An implant-retained overdenture may be indicated in patients with changed anatomy, neuromuscular disorders, significant gag reflex or considerable ridge resorption (Vere, Bhakta, Patel, 2012).

Implant-retained overdentures may reduce residual ridge resorption and enhance mastication and hence nutritional status, improve speech and patient self-esteem (Doundoulakis et al, 2003).

## Retention of implant-retained overdentures

Overdentures may be retained by a number of different implants, which can be splinted or separate (Dudic, Merickse-Stern, 2002). Authors have reported high implant survival rates for mandibular overdentures and thus successful treatment outcomes when overdentures are retained by two implants (Meijer et al, 2009) splinted or non-splinted. In the maxilla, the evidence base supports the use of four to six implants splinted with a bar, although freestanding abutments are increasing in popularity (Galluci, Morton, Weber, 2008). There are various prosthetic options and attachments that are available to provide a satisfactory overdenture.

## Attachment selection

### 1. Bar and clip systems

The major bar types come with matching clips.

The use of the spacer enables a space between the clip and the bar when the prosthesis is at rest in the patient's mouth. Upon biting, the denture is capable of some vertical movement so that there is some support for occlusal loads instead of purely implant support.

Milled bars do not allow movement of the denture base and can provide relief over painful areas such as superficial mental nerves (Dudic and Merickse-Stern, 2002). A cast bar may be made including proprietary components, or a custom design can be fabricated. Subsequently, the denture is made to fit over the custom design.

Both rigid and resilient bars can be used to align non-parallel implants. However, they need at least 10 mm of interocclusal clearance and should not be used when vertical space is limited (Chee and Jivraj, 2006).

### 2. Studs

All stud attachments should be parallel to each other and the attachments should not interfere with the insertion path of the overdenture.

### 3. Magnets

Magnets provide the least retention.

### 4. Telescopic copings (rigid and non-rigid)

Note that patients with advanced resorption of the ridge are suitable for bar or telescopic attachment assemblies that offer horizontal stability. Patients with minimal alveolar resorption of the ridge are suitable for studs or magnetic attachment assemblies.

## Case Study

This patient initially presented with both upper laterals fractured at the gum line (Fig. 1). Teeth 26 and 24 were missing.

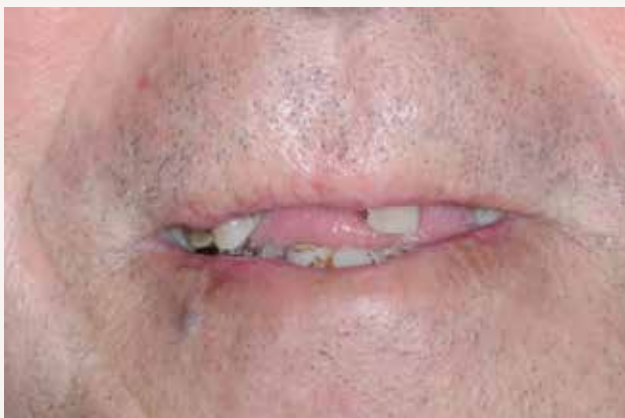

Fig. 1

Intraoral examination indicated evidence of generalised moderate to severe periodontitis.

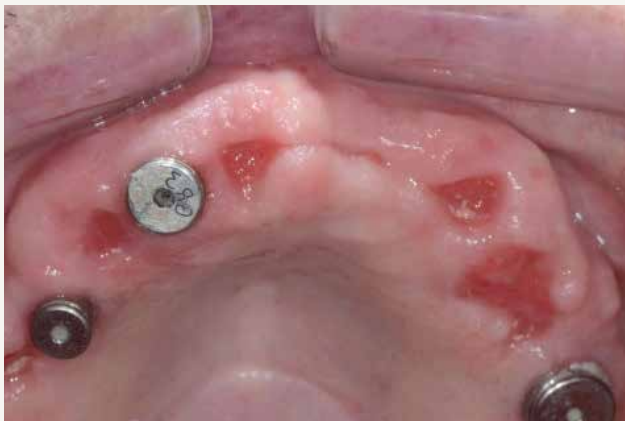The following options were discussed with the patient:

1. Full denture
2. Partial denture
3. Bar-retained full denture.
4. Replacement of missing /unrestorable teeth with implant/crowns.

The patient decided on option 4 with a view of option 3 in the future.

Surgical Procedure:

- The laterals were extracted. Implants surgery was then carried out 6 weeks later.
- The laterals were replaced with 4mm x 12mm Parallel BioHorizons implants.
- A 3.5mm x 12mm implant was placed in the 24 area and a 5.0 x 12mm implant in the 16 area.
- The surgery was uneventful. A temporary bridge was then constructed using the canines and centrals as abutments.
- Two weeks post surgery the patient complained of pain in the 12 implant area. An intra-oral exam revealed fluctuant swelling in the buccal tissues apical to tooth 11. A periapical radiography revealed periapical pathology and a decision was made to remove tooth 11.
- The patient then made a decision to have all remaining teeth removed and implement option 3. A week later, implant 12 failed to integrate and became loose. It was clear that the infection from the 11 had compromised the adjacent implant.



**Fig. 2**

Dentist/Laboratory Communication:

- Upon consultation with the technician, the dentist decided to make an immediate full upper denture.
- Subsequently all remaining teeth, 18, 17, 15, 14, 13, 23, 25 were extracted and the full upper denture inserted (Fig. 2).

#### Preliminary Work-up:

- 3 months later following uneventful healing, a replica of the full upper denture was made with clear cold cured acrylic and 6 radiographic markers placed. A CT scan was made of the maxilla with the Radiographic Guide in Place. The Guide was then scanned on its own in a soft tissue window.
- Using software, the two scans were merged using the radiographic markers to align the images (Figs. 3-6 ). Three more implants were than planned so that the total number of implants would be six. The new implants were then inserted in the 11, 13 and 15 position.

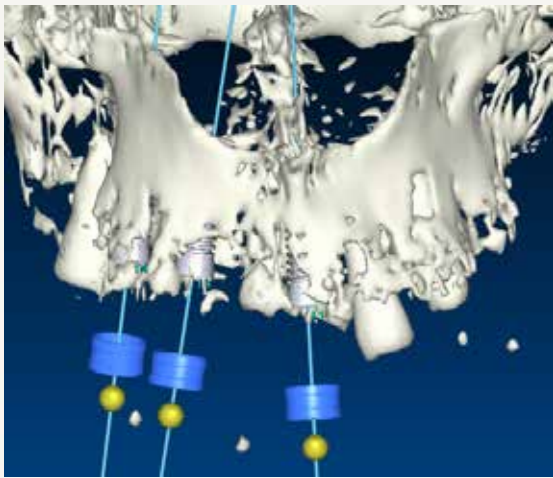


Fig. 3

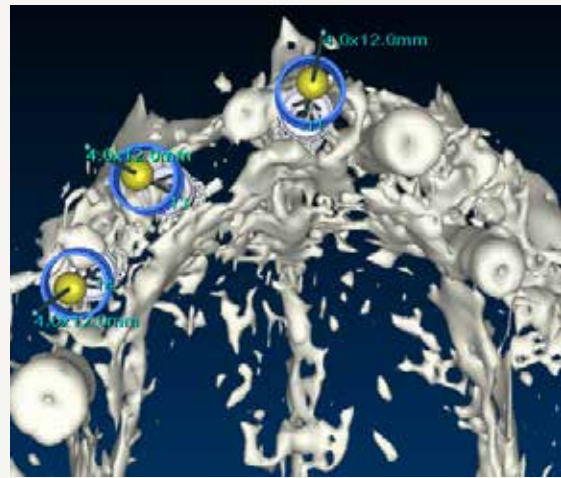


Fig. 4

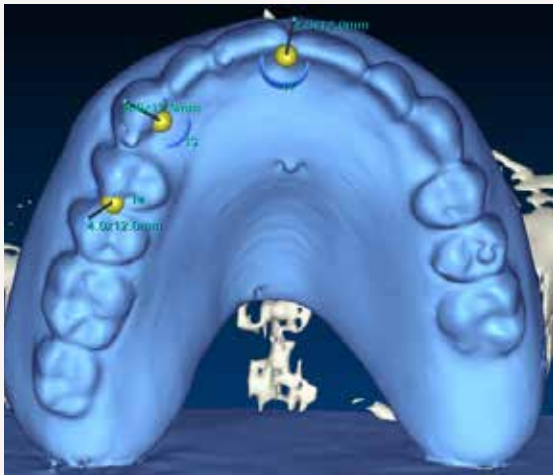


Fig. 5

- An external sinus lift was offered to the patient so that a 16 implant could be placed but the patient was strongly against any type of invasive surgery. An internal lift was not possible due to a very uneven sinus floor making a perforation a probable scenario.
- It was decided that a cantilever bar to the 16 area was a good compromise considering that there were six implants in total.

#### Prosthetic Phase:

- After a further three months post implant surgery, a review appointment revealed the recent implants had all successfully integrated. An open special tray final impression was taken after the implants were rigidly fixed together.
- A custom milled bar was then manufactured by the laboratory and tried in for passive seating (Fig. 6).

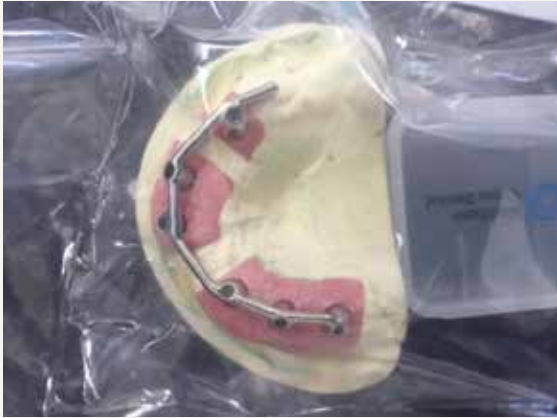

Fig. 6

- An excellent result was obtained (Fig. 7). On confirmation of passive seating of the bar, an acrylic/ wax plate was made using three implants as an anchor point. This enabled a precise interocclusal registration to be carried out.
- The laboratory then finished the case by make a Co-Cr upper full denture without any palatal coverage. The milled bar was torqued down to the 30Ncm level and the plate inserted over it (Fig. 8).

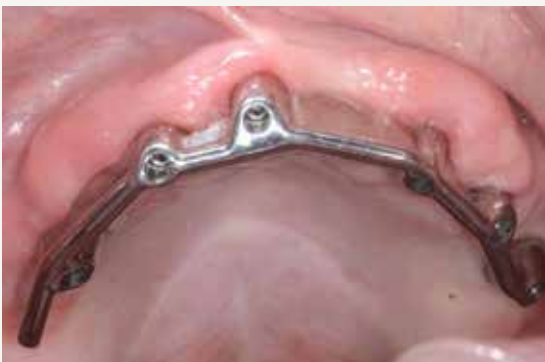

Fig. 7

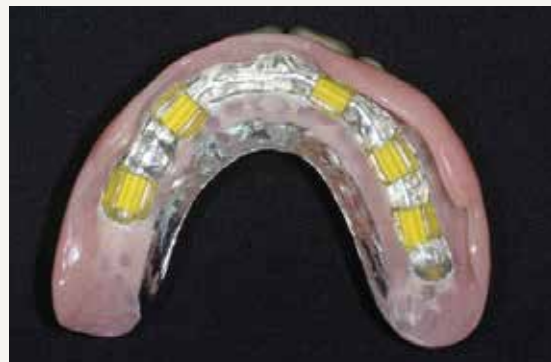

Fig. 8

- Excellent retention was obtained.
- Clear instructions were given to the patient on how to clean around and underneath the bar. A review appointment two weeks after insertion of the final prosthesis revealed the patient was maintaining excellent oral hygiene.
- A slight bite adjustment was made on a premature posterior contact.
- The patient was delighted with the final aesthetics.

Southern Cross Dental would like to thank Dr Cameron Castle, Bundaberg, Queensland for his case submission. Dr Castle has a restoratively-based practice specialising in complex rehabilitation of debilitated dentitions.

## BIBLIOGRAPHY

Chee, W. and Jivraj, S., 2006. Screw versus cemented implant supported restorations. *British dental journal*, 201(8), pp.501-507.

Doundoulakis, J.H., ECKERT, S.E., LINDQUIST, C.C. and JEFFCOAT, M.K., 2003. The implant-supported overdenture as an alternative to the complete mandibular denture. *The Journal of the American Dental Association*, 134(11), pp.1455-1458.

Dudic, A. and Mericske Stern, R., 2002. Retention Mechanisms and Prosthetic Complications of Implant Supported Mandibular Overdentures: Long Term Results. *Clinical implant dentistry and related research*, 4(4), pp.212-219.

Gallucci, G.O., Morton, D. and Weber, H.P., 2009. Loading protocols for dental implants in edentulous patients. *International Journal of Oral & Maxillofacial Implants*, 24.

Meijer, H.J., Raghoobar, G.M., Batenburg, R.H., Visser, A. and Vissink, A., 2009. Mandibular overdentures supported by two or four endosseous implants: a 10 year clinical trial. *Clinical Oral Implants Research*, 20(7), pp.722-728.

Vere, J., Bhakta, S. and Patel, R., 2012. Implant-retained overdentures: a review. *Dental update*, 39(5), pp.370-2.